

Original Research Article**Analysis of Cervico- Vaginal Lesions in Women using Pap Smear: A Histopathological Study****Anand Nagalikar¹, Rashmi Chandragouda Meti²**

¹Associate Professor, Department of Pathology, ESIC Medical College, Gulbarga, Karnataka 585106, India. ²Associate Professor, Department of Microbiology, Kamineni Institute of Medical Sciences, Narketpalli, Nalgonda, Telangana 508254, India.

Abstract

Background: Cervical cancer is one of the leading cancers in women. The confirmation of the disorder can be possible by Pap smear. The present study was conducted to assess the cases of cervical cancer in women using cervical Pap smear.

Corresponding Author:**Rashmi Chandragouda Meti,**

Associate Professor,
Department of Microbiology,
Kamineni Institute of Medical
Sciences, Narketpalli, Nalgonda,
Telangana 508254, India.

E-mail:

anagalikar@gmail.com

(Received on 17.03.2018,

Accepted on 04.04.2018)

Materials & Methods: This study was conducted in the Department of Pathology, ESIC Medical College, Gulbarga, Karnataka (India) on 1080 cervico-vaginal smears which were checked for the epithelial abnormalities such as atypical squamous cells of uncertain significance (ASCUS), low-grade squamous intraepithelial lesion (LSIL), non neoplastic intraepithelial lesion (NILM), high-grade squamous intraepithelial lesion (HSIL) and squamous cell carcinoma (SCC).

Results: Among 1080 Pap smears, 35 were unsatisfactory, 990 were NILM, 32 were LSIL, 10 were HSIL, 5 were SCC and 8 were ASCUS. The difference was significant (0.01). 1 case of ASCUS, 2 cases of LSIL were seen in age group 31-40 years. 2 cases of ASCUS, 3 cases of LSIL and 1 case of HSIL was seen in age group 41-50 years, 2 cases of ASCUS, 22 cases of LSIL, 6 cases of HSIL were seen in age group 51-60 years, 5 cases of LSIL, 3 cases of were seen in age group 61-70 years. 3 cases of ASCUS were seen in age group 71-80 years. The difference was significant (P- 0.01). The various changes were atrophy (30), non-specific inflammation (55), trichomoniasis (10), candidiasis (25), reactive (25), no other changes (840) and bacterial vaginosis (5). The difference was significant (P- 0.01).

Conclusion: Cervical cancer is one of the leading cause of death in women. Pap smear is considered to be effective in detection of lesions in women. It is economical and non sophisticated procedure. Careful Pap smear analysis can be proved beneficial in preventing lesions.

Keywords: Cervical Cancer; Smear; Trichomoniasis.

Introduction

Cervical cancer is a cancer arising from the cervix. It is leading cause of cancer in women. It constitutes approximately 5 lacs new cases annually. In India it is estimated, that the number of cases are over 1.5 lacs. It is due to the abnormal growth of cells that have the ability to invade or spread to other parts of the body [1].

Infection with some types of HPV is the greatest risk factor for cervical cancer, followed by smoking. HIV infection is also a risk factor. Not all of the causes of cervical cancer are known, however, and several other contributing factors have been implicated. Early on, typically no symptoms are seen. Later symptoms may include abnormal vaginal bleeding, pelvic pain, or pain during sexual intercourse. While bleeding after sex may not be serious, it may also indicate the presence of cervical cancer [2].

The Pap smear can be used as a screening test, but is false negative in up to 50% of cases of cervical cancer. Confirmation of the diagnosis of cervical cancer or precancer requires a biopsy of the cervix. This is often done through colposcopy, a magnified visual inspection of the cervix aided by using a dilute acetic acid solution to highlight abnormal cells on the surface of the cervix. Medical devices used for biopsy of the cervix include punch forceps, Spira Brush CX, Soft Biopsy, or Soft-ECC [3]. The present study was conducted to analyze cervico-vaginal lesions in women using Pap smears.

Materials & Methods

This study was conducted in the Department of Pathology, ESIC Medical College, Gulbarga, Karnataka, India. It included 1080 cervico-vaginal smears. All were informed regarding the study and written consent was obtained. For smear collections, the samples were collected using Ayer’s spatula or an endocervical brush. The smears were then fixed in alcohol and stained using the Papanicolaou’s technique.

All smears were reported using modified Bethesda System. The epithelial abnormalities were classified as atypical squamous cells of uncertain significance (ASCUS), low-grade squamous intraepithelial lesion

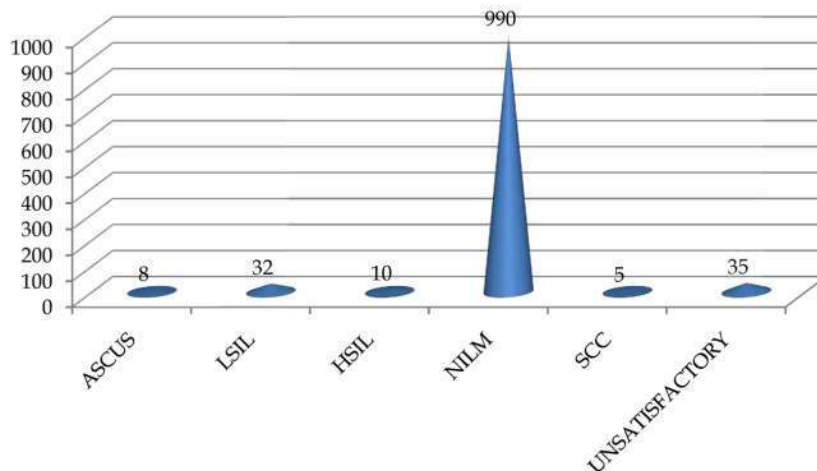
(LSIL), non neoplastic intraepithelial lesion (NILM), high-grade squamous intraepithelial lesion (HSIL) and squamous cell carcinoma (SCC). Results thus obtained were subjected to statistical analysis. P value < 0.05 was considered significant.

Results

Graph 1 shows that among 1080 Pap smears, 35 were unsatisfactory, 990 were NILM, 32 were LSIL, 10 were HSIL, 5 were SCC and 8 were ASCUS. The difference was significant (0.01).

Graph 2 shows that 1 case of ASCUS, 2 cases of LSIL were seen in age group 31-40 years. 2 cases of ASCUS, 3 cases of LSIL and 1 case of HSIL was seen in age group 41-50 years, 2 cases of ASCUS, 22 cases of LSIL, 6 cases of HSIL were seen in age group 51-60 years, 5 cases of LSIL, 3 cases of were seen in age group 61-70 years. 3 cases of ASCUS were seen in age group 71-80 years. The difference was significant (P- 0.01).

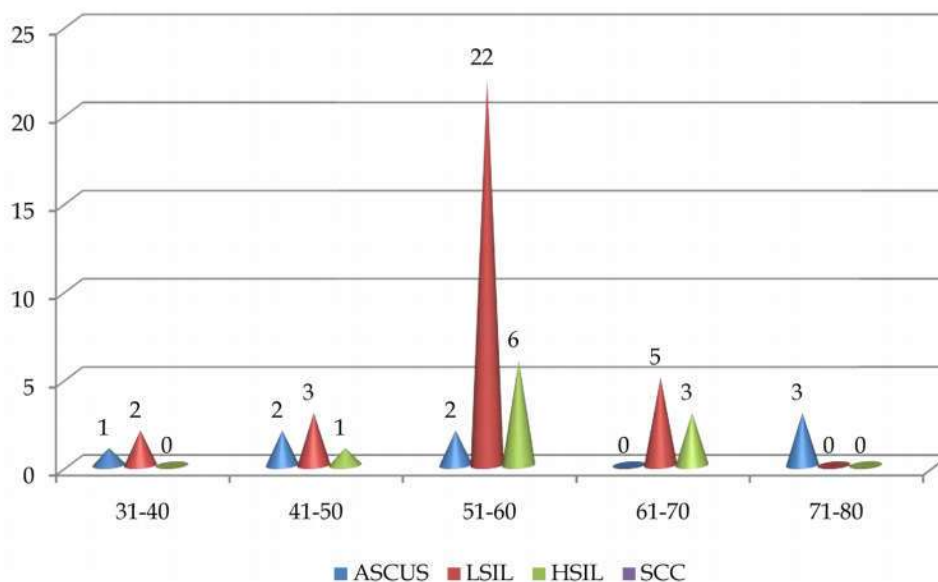
Table 1 shows that various changes were atrophy (30), non-specific inflammation (55), trichomoniasis (10), candidiasis (25), reactive (25), no other changes (840) and bacterial vaginosis (5). The difference was significant (P- 0.01).



Graph 1: Distribution of patients

Table 1: Non neoplastic cytological diagnosis in pap smear

Signs	Number	P value
Atrophy	30	0.01
Non specific inflammation	55	
Trichomoniasis	10	
Candidiasis	25	
Bacterial Vaginosis	5	
Reactive changes	25	
No other changes	840	



Graph 2: Age related distribution of patients

Discussion

Human papillomavirus (HPV) infection appears to be involved in the development of more than 90% of cases; most people who have had HPV infections, however, do not develop cervical cancer. Other risk factors include smoking, a weak immune system, birth control pills, starting sex at a young age, and having many sexual partners, but these are less important. The role of the Pap smear as a cancer screening tool for the cervix has been substantiated by several studies in the last 50 years and the method has resulted in falling incidence and mortality rates of cervical cancer in the developed world [4].

Papanicolaou (Pap) smear testing is an effective method of detecting, preventing and delaying the progress of cervical cancer. Even as liquid-based cytology is popular in the developed countries, in low resource settings, a conventional Pap test is the main screening system. It is a well-known fact that the burden of cervical cancer has been reduced dramatically after the introduction of screening programmes [5].

We found that among 1080 Pap smears, 35 were unsatisfactory, 990 were NILM, 32 were LSIL, 10 were HSIL, 5 were SCC and 8 were ASCUS. Our results are in agreement with Bal MS et al [5]. We found that maximum lesions were seen in age group of 51-60 years. This is in agreement with Patel M et al [6]. However, Gupta K [7] reported higher prevalence in age group 31-40 years. This is in agreement with Sarma U et al [8].

We found that various changes were atrophy (30), non-specific inflammation (55), trichomoniasis (10), candidiasis (25), reactive (25), no other changes (840) and bacterial

vaginosis (5). Pap smear testing is a very useful, simple, economical and safe tool to detect pre invasive cervical epithelial lesions. This is similar to Banik et al [9].

A study by Geetu et al. [10] found a total of 2028 cases. 49 (2.41%) cases revealed epithelial abnormalities. The most frequent epithelial cell abnormality was low grade squamous intra epithelial Lesion (32 cases, 1.58%). Nearly half of the patients with abnormal pap smears presented with a normal looking cervix. Epithelial abnormality was more prevalent in post-menopausal age group. Hence on a routine basis, every woman above the age of 30 must be subjected to Pap smear and this must be continued even in post-menopausal period as most of patients with epithelial abnormalities in our study falls in this group.

Conclusion

Cervical cancer is one of the leading cause of death in women. Pap smear is considered to be effective in detection of lesions in women. It is economical and non sophisticated procedure. Careful Pap smear analysis can be proved beneficial in preventing lesions.

References

1. Ali F, Kuelker R, Wassie B. Understanding cervical cancer in the context of developing countries. *Ann Trop Med Public Health* 2012;22(5):3-15.
2. Denny L. The prevention of cervical cancer in developing countries. *BJOG* 2005;112:1204-12.

3. Solomon D, Davey D, Kurman R et al. The 2001 Bethesda system: Terminology for Reporting Results of Cervical Cytology. *JAMA*2002;287:2114-19.
 4. Bal MS, Malik NP, Sharma VK, Verma N, Gupta A. Prevalence of cervical dysplasia in western Uttar Pradesh. *J Cytol* 2013; 30:257-62.
 5. Patel MM, Pandya AN, Modi J. Cervical Papsmear study and its utility in cancer screening, to specify the strategy for cervical cancer control. *Nat J Com Med* 2011;1:49-51.
 6. Gupta, Goyal R, Suri AK, Mohi MK. Detection of abnormal cervical cytology in Papanicolaou smears. *J Cytol* 2012;29: 45-7.
 7. Sarma U, Mahanta J, Talukdar K. Pattern of Abnormal Cervical Cytology in women attending a Tertiary Hospital. *IJSRP*2012;2.
 8. Gupta K, Malik NP, Sharma VK, Verma N, Gupta A. Prevalence of cervical dysplasia in western Uttar Pradesh. *J Cytol* 2013; 30:257-62.
 9. Banik U, Bhattacharjee P, Ahamad SU, Rahman Z. Pattern of epithelial cell abnormality in Papsmear: A clinicopathological and demographic correlation. *Cytojournal* 2011;8:8.
 10. Geetu, Changhua, Wen F. Clinical utility of Liqui-PREPTM cytology system for primary cervical cancer screening in a large urban hospital setting in China. *J Cytol* 2009;26:20-5.
-